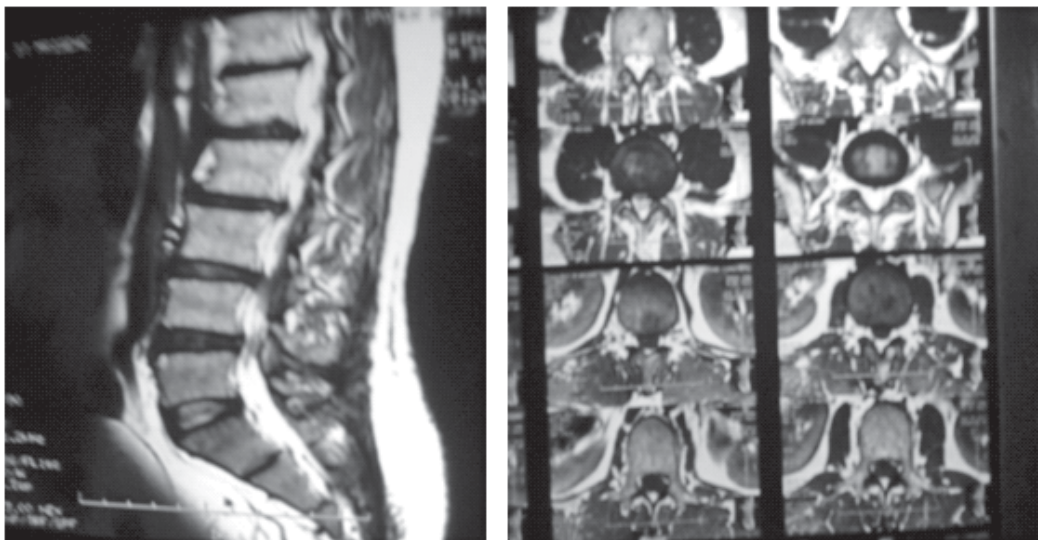


REHAB CHALLENGES

39 year male patient presented in PMR OPD with severe low back pain (VAS score 8 out of 10) with both lower limb radiation. After conservative therapy with lumbosacral orthoses, standardized exercise schedule, analgesics, muscle relaxant, pregabalin etc. pain score was not improved significantly. On clinical examination there are right L3 and L5 sensory radiculopathy and left sided L5 and S1 sensory changes without any motor deficit. MRI picture of his lumbosacral spine clearly showed multiple levels PIVD like disc bulge in L4/5 and L5/S1 and disc desiccations in L2/3.



MRI of lumbosacral spine

The patient is unable to do his ADL for last few weeks. Please opine regarding specific interventional pain management approach.