

PG Forum

REHAB CHALLENGES

A 6 months old female child presented to PMR OPD with dorsolumbar scoliosis (Fig 1) noticed by parents 2 months ago. The baby was otherwise asymptomatic apart from poor sitting balance with support. When we examined the baby we saw a hollowness (Fig 2) in left infra-axillary area. On further examination there was no objective neurological deficit and the curvature persisted on sitting.

On further imaging on x-ray showed a Cobbs angle of 35°. Chest x-ray (Fig 3) showed absent 7, 8, 9 ribs. Considering the congenital absence of ribs we suggested a CT abdomen and thorax (Fig 4) which confirmed the absent rib without absent of any lung segment and other organ anomaly.

We counselled the parents regarding further management and prognosis and put her on posture correction and exercise therapy. But the dilemma started with the prescription of spinal orthosis for the scoliosis.

Please opine regarding orthotic prescription of this young girl.

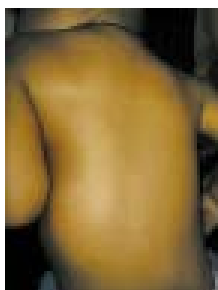

Fig 1

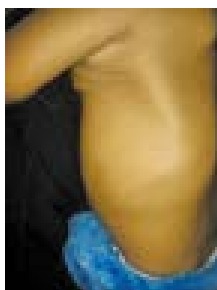


Fig 2

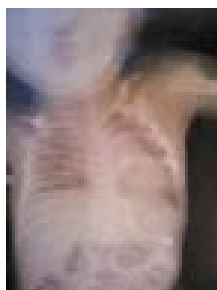

Fig 3

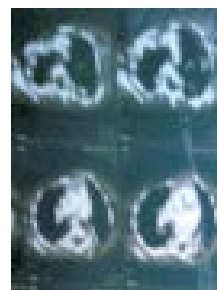

Fig 4