

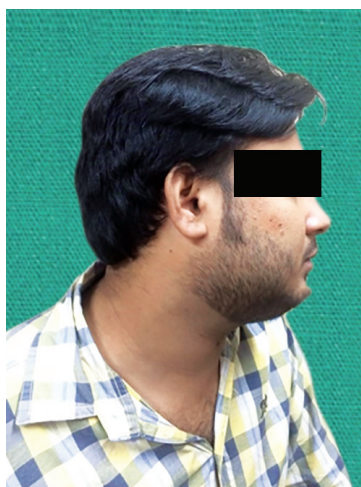## Pictorial Continuing Medical Education

### Anterior Neck Pain Due to Stylalgia

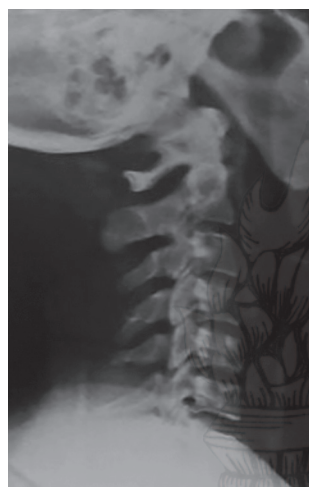
A 28 years old young male (Fig. 1) presented in PMR OPD at IPGMER, SSKM&H with severe right-sided anterior neck pain for last 8 months. He was in agony due to incapacitating pain which worsened on movement of the neck to right side. ENT examination did not reveal any specific throat or oral pathology.

On examination there was tenderness present on right anterior neck region along with painful cervical rotation of right side of the neck. There was no history of sudden loss of consciousness or any focal neurodeficit. Digital X-ray of cervical spine shows enlarged styloid process (Fig. 2).

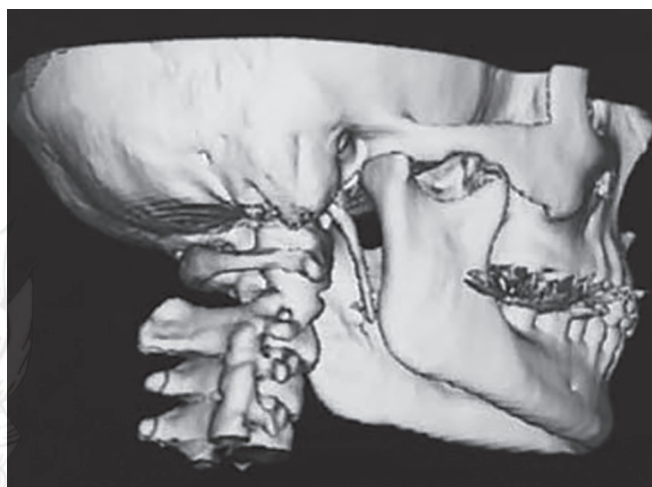Hence, a diagnosis of stylalgia was made and a 3D CT scan of neck was advised to rule out any possibility of developing an Eagle's syndrome. Eventually 3D CT shows enlarged styloid process without compressing any vascular structure (Fig. 3). Patient was improved with NSAIDS, physical modalities and exercises.



**Fig. 1:** Young male with severe right sided anterior neck pain



**Fig. 2:** Digital X-ray of cervical spine shows enlarged styloid process



**Fig. 3:** 3D CT shows enlarged styloid process without compressing any vascular structure

