

## CASE REPORT

# Spondylocostal Dysostosis with Sprengel Deformity: A Case Report

Anuradha D Shenoy<sup>1</sup>, Mahesh Choudhary<sup>2</sup>, Shefali Gupta<sup>3</sup>, Anil K Gaur<sup>4</sup>

### ABSTRACT

Spondylocostal dysostosis is a term given to a heterogeneous group of disorders characterized by abnormal vertebral segmentation, malalignment of ribs with variable points of intercostal fusion, and often a reduction in rib number. Sprengel deformity is characterized by abnormal development and elevation of scapula.

**Keywords:** Jarcho–Levin syndrome, Spondylocostal dysostosis, Sprengel deformity.

*Indian Journal of Physical Medicine & Rehabilitation* (2018); 10.5005/jip-journals-10066-0033

### INTRODUCTION

Spondylocostal dysostosis is a rare genetic disorder characterized by the defect of vertebrae and anomalies of ribs.<sup>1</sup> Main skeletal malformation includes fusion of vertebrae, hemivertebrae, and rib fusion with other rib malformation. These children have short neck, short trunk, scoliosis, or kyphosis. They may experience difficulty and repeated chest infection.

Sprengel deformity is a congenital condition characterized by abnormal development and elevation of scapula; signs and symptoms include lump in back of neck and limited movement in shoulder or arm.

### CASE DESCRIPTION

A nine-year-old female second child of her parents born out of nonconsanguineous marriage was brought by father with complaints of deformity of left shoulder. Antenatal and perinatal periods were uneventful. In postnatal period from age of one and half months, she was experiencing multiple episodes of respiratory infection and on further investigation was found to have chest wall abnormality. Presently, she complains of breathlessness on activity. Since last 3–4 months, she is free of any respiratory symptoms. Her only elder sibling does not have such complaints and is normal for his age.

On examination, her height was 114 cm (<3rd percentile), US to LS ratio was 1.1, and weight was 18 kg (<3rd percentile). Shoulder asymmetry was seen with left shoulder at higher level than right shoulder as shown in Figure 1A. No scoliosis was seen. Cervical as well as shoulder range of motion was full. On palpation, a defect was found in left axilla along 4th–6th rib. Other system examination was within normal limits (Fig. 1B).

On imaging chest X-ray showed: broad and fused rib in left side involving 6th, 7th, and 8th rib in posterior end; bifid anterior 8th rib and narrow hemithorax; left scapula is elevated and medially rotated with superomedial angle of scapula located at level of D5–D6 disk space Rigault classification group II; increased acromiohumeral distance on left side; Multiple congenital anomalies seen from D2 to D7 as shown in Figure 2A and congenital deformed butterfly vertebrae from D2 to D4 level with anterior wedging in lateral view as shown in Figure 2B.

PFT done showed severe restriction.

USG abdomen done was normal.

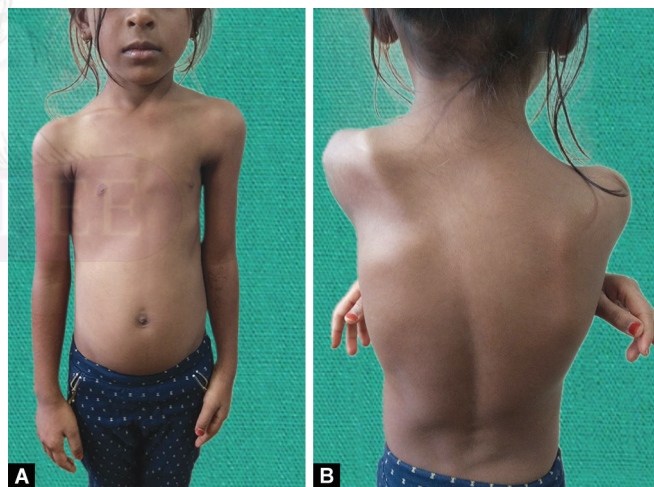<sup>1–4</sup>Department of Physical Medicine and Rehabilitation, All India Institute of Physical Medicine and Rehabilitation, Mumbai, Maharashtra, India

**Corresponding Author:** Mahesh Choudhary, Department of Physical Medicine and Rehabilitation, All India Institute of Physical Medicine and Rehabilitation, Mumbai, Maharashtra, India, Phone: +91 9920083839, e-mail: drmahichoudhary@gmail.com

**How to cite this article:** Shenoy AD, Choudhary M, *et al.* Spondylocostal Dysostosis with Sprengel Deformity: A Case Report. *Indian J Phys Med Rehab* 2018;29(4):110–111.

**Source of support:** Nil

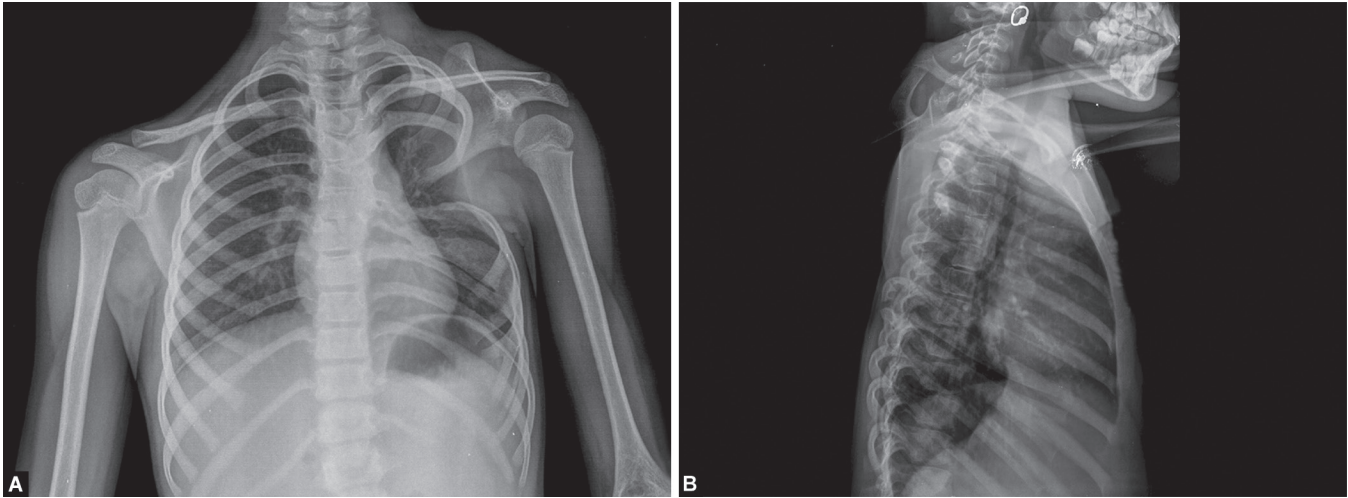
**Conflict of interest:** None



**FIGS 1A and B:** (A) Left-side shoulder at higher level than right; (B) Left hypoplastic scapula

### DISCUSSION

Spondylocostal dysostosis is a clinoradiological entity defined radiologically as multiple segmentation defect of vertebrae in combination with abnormalities of ribs. Clinically, there is short trunk in proportion to height, short neck, nonprogressive scoliosis in most affected individuals. Due to reduced size of thorax, respiratory



**Figs 2A and B:** (A) Chest X-ray PA view; (B) X-ray dorsal spine lateral view

function may be impaired in neonates,<sup>2,3</sup> as seen in our patient who had multiple episode of respiratory tract infection which has been reduced since the last 3–4 months. Multiple vertebral anomalies include butterfly vertebrae, hemivertebrae, and fused hypoplastic vertebrae may be present.<sup>4</sup> Ribs may be fused together, misaligned, broadened, spilt, or bifid.

Most cases are inherited in autosomal recessive pattern caused by mutation in one of four genes: DLL3, MESP2, LFNG, and HESF. Rarely, it can be inherited in autosomal dominant manner. One gene, TBX6, is known to cause autosomal dominant spondylocostal dysostosis.<sup>4,5</sup>

Associated anomalies include spina bifida, meningomyelocele, complex congenital heart disease, atrial septal defect, hypospadias, and ureteral abnormality. Intelligence is unaffected and neurological complication is rare. In this patient, no such associated anomalies were seen.<sup>1</sup>

Sprengel deformity is a congenital condition caused interruption of normal development and movement of scapula during early fetal growth.<sup>6</sup> Sprengel deformity might be associated with fused or absent ribs, cervical rib, or spina bifida.<sup>7</sup> Rigault classified deformity into 3 groups:

- Group I—superomedial angle lower than T2 but above T4 process
- Group II—superomedial angle located between C5 and T2 transverse process
- Group III—superomedial angle above C5 transverse process

## CONCLUSION

In our patient, sprengel deformity on imaging was found to have multiple anomaly of ribs on left side and vertebral anomalies, which were compatible with spondylocostal dysostosis. The case was reported because of its extremely rare presentation.

## REFERENCE

1. Spondylocostal Dysplasia—NORD (National Organization for Rare Disorders) [Internet]. NORD (National Organization for Rare Disorders). 2018 [cited 5 August 2018]. Available from: <https://rarediseases.org/rare-diseases/jarcho-levin-syndrome/>.
2. Balaji S, Indu SV, et al. Spondylocostal Dysostosis with Sprengel Deformity: A Rare Association. *Int J Pediatr Res* 2014;1(2):54–57. DOI: 10.17511/ijpr.2014.02.05.
3. Kulkarni M, Sarfaraz Navaz R, et al. Jarcho-Levin syndrome. *Indian J Pediatr* 2006;73(3):245–247. DOI: 10.1007/bf02825493.
4. OMIM Entry - # 277300 - SPONDYLOCOSTAL DYSOSTOSIS 1, AUTOSOMAL RECESSIVE; SCDO1 [Internet]. Omim.org. 2018 [cited 5 August 2018]. Available from: <https://www.omim.org/entry/277300>.
5. Bindu CM, Krishnappa J, et al. Jarcho-Levin syndrome (spondylocostal dysostosis) associated with Sprengel deformity. *J Clin Sci Res* 2017; 6(1):46–49.
6. Bhatia D, DasGupta B, et al. Sprengel's deformity of the shoulder: Current perspectives in management. *Int J Shoulder Surg* 2011;5(1): 1–8. DOI: 10.4103/0973-6042.80459.
7. Vijayan S, Shah H. Spondylo-costal dysostosis with Sprengel's shoulder – Report of a new association with Jarcho-Levin syndrome. *kjo* 2012 Jul 10;25(2):103–104.